



Patient

NHS No

D.O.B.

Patient Ref

Reason

Claudication

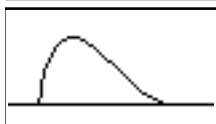
Outcome

Not viewed, Obscured, Bowel gas, Poor images, patient habitus, Significant disease indicated

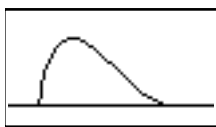
## Right

140

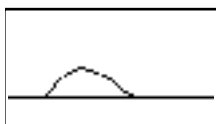
1.00



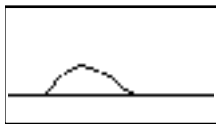
Reduced



Reduced



Weak



Weak

100

0.71

Brachial

Common Femoral

High Thigh

Low Thigh

Popliteal

High Calf

Peroneal

Anterior Tibial

Posterior Tibial

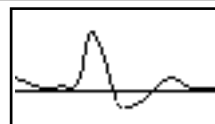
Dorsalis Pedis

Toe Pressure

Post Exercise

## Left

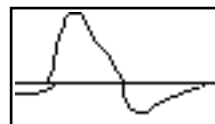
Good



Slightly Reduced

140

1.00



## Notes

## RIGHT LOWER LIMB ARTERIAL DUPLEX SCAN

Abdominal aorta and abdominal vessels not clearly visualised due to patient's body habitus, depth of the vessels and bowel gas.

EIA (distal): appears patent with monophasic waveforms, PSV 92cm/s ?more proximal significant disease.

CFA: appears mildly diseased, reduced monophasic waveforms, PSV 89cm/s.

PFA: appears moderately diseased, turbulent monophasic waveforms, PSV 95cm/s.

Assessed by

Lukasz Koprowski

Checked by



---

Patient

NHS No

D.O.B.

Patient Ref

---

SFA: appears patent throughout its length, reduced monophasic waveforms, PSV 64-26cm/s.

POPA: appears patent, reduced monophasic waveforms, PSV 23cm/s.

TPT: appears patent, 2 vessel run-off noted.

ATA: appears patent at the ankle, weak monophasic waveforms, PSV 13cm/s.

PTA: appears patent at the ankle, weak monophasic waveforms, PSV 13cm/s.

Left CFA: appears moderately diseased, good triphasic waveforms, PSV 189cm/s.

SUGGEST ALTERNATIVE IMAGING MODALITY FOR THE ABDOMINAL REGION, IF APPROPRIATE.

---

Assessed by

Lukasz Koprowski

Checked by

---